

March 2019 Pulmonary Case of the Month: A 59-Year-Old Woman with Fatigue

Lewis J. Wesselius, MD¹

Michael B. Gotway, MD²

¹Department of Pulmonary Medicine and ²Department of Radiology
Mayo Clinic Arizona
Scottsdale, AZ USA

History of Present Illness

A 59-year-old woman from Kingman, Arizona had a one-year history of fatigue with some shortness of breath. For this reason, she saw her primary care physician.

Past Medical History, Social History and Family History

She has no significant past medical history. She does not smoke. Family history is noncontributory.

Physical Examination

Physical examination was unremarkable.

Which of the following ***should be done***?

1. Chest x-ray
2. Complete blood count
3. Electrolytes, blood urea nitrogen and creatinine
4. Liver panel
5. All of the above

Correct!
5. All of the above

The value of annual physical exams and blood tests has been questioned by the Choosing Wisely campaign (1). In asymptomatic individuals, annual physical examinations and routine blood tests appear to do little good and false positives often lead to additional unnecessary evaluations and/or laboratory tests. However, our patient is not asymptomatic although the complaints of fatigue and shortness of breath are nonspecific. All the blood tests were performed and were normal. A chest x-ray was also performed (Figure 1).

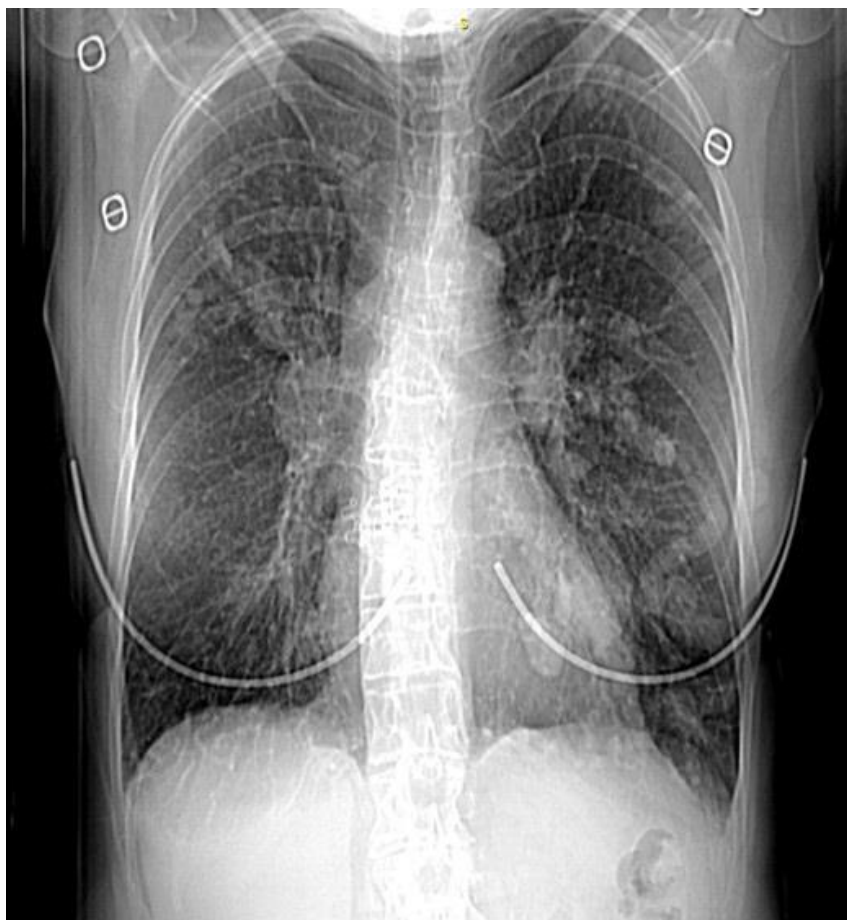


Figure 1. Initial PA chest radiograph.

Which of the following is/are the **best interpretation(s)** of the chest radiograph?

1. Hyperinflation
2. Multiple pulmonary opacities
3. Normal
4. 1 and 3
5. All of the above

Correct!

2. Multiple pulmonary opacities

The chest is long and narrow but the lungs are not hyperinflated. The vasculature does not appear reduced and there is no evidence for flattening of the diaphragms although this is best seen on the lateral view. There are multiple pulmonary opacities of varying sizes and shapes present (Figure 2).

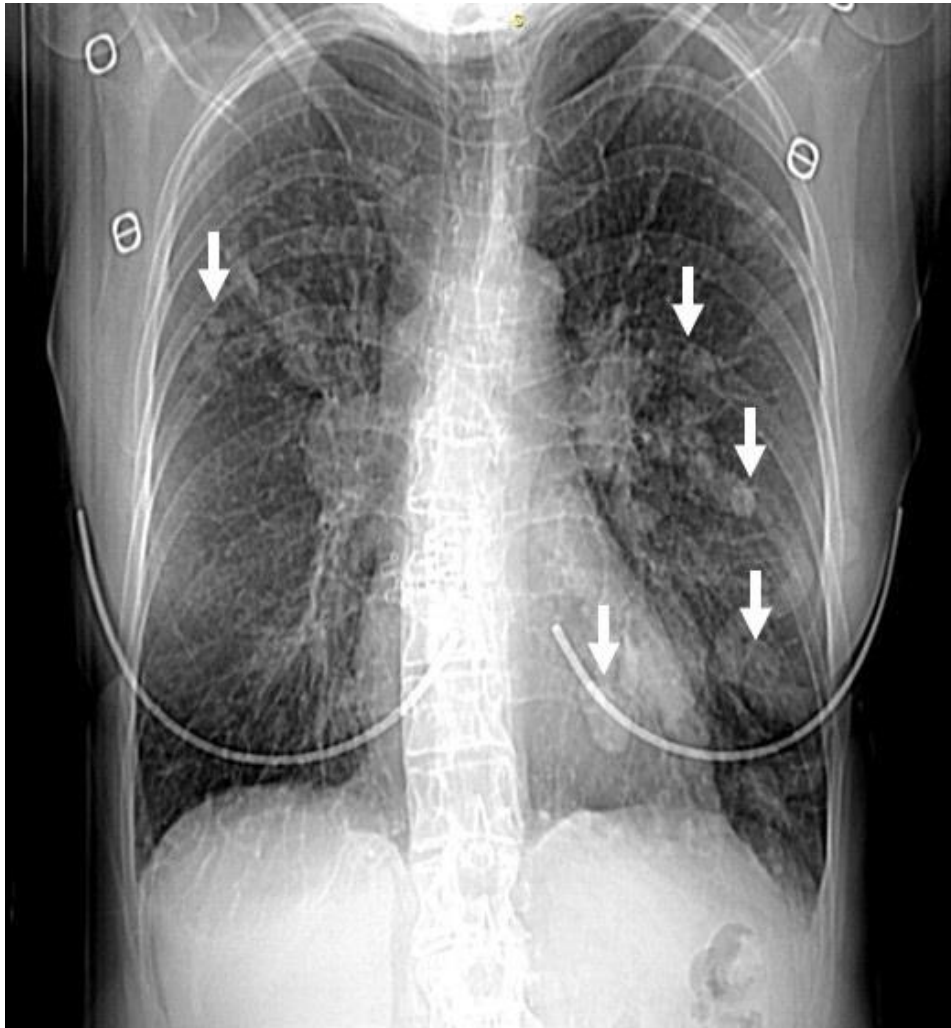


Figure 2. Chest radiograph with multiple pulmonary opacities (arrows).

What should be **done next?**

1. Bronchoscopy with transbronchial biopsy
2. Percutaneous needle biopsy
3. Thoracic CT scan with contrast
4. Thoracic CT scan without contrast
5. Video-assisted thoracotomy (VATS)

Correct!

3. Thoracic CT scan with contrast

CT scan will better define the opacities and allow visualization of the rest of the chest. Contrast will assess the vascular nature of the nodules. Biopsy is premature.

A thoracic CT scan with and without contrast was performed (Figure 3).

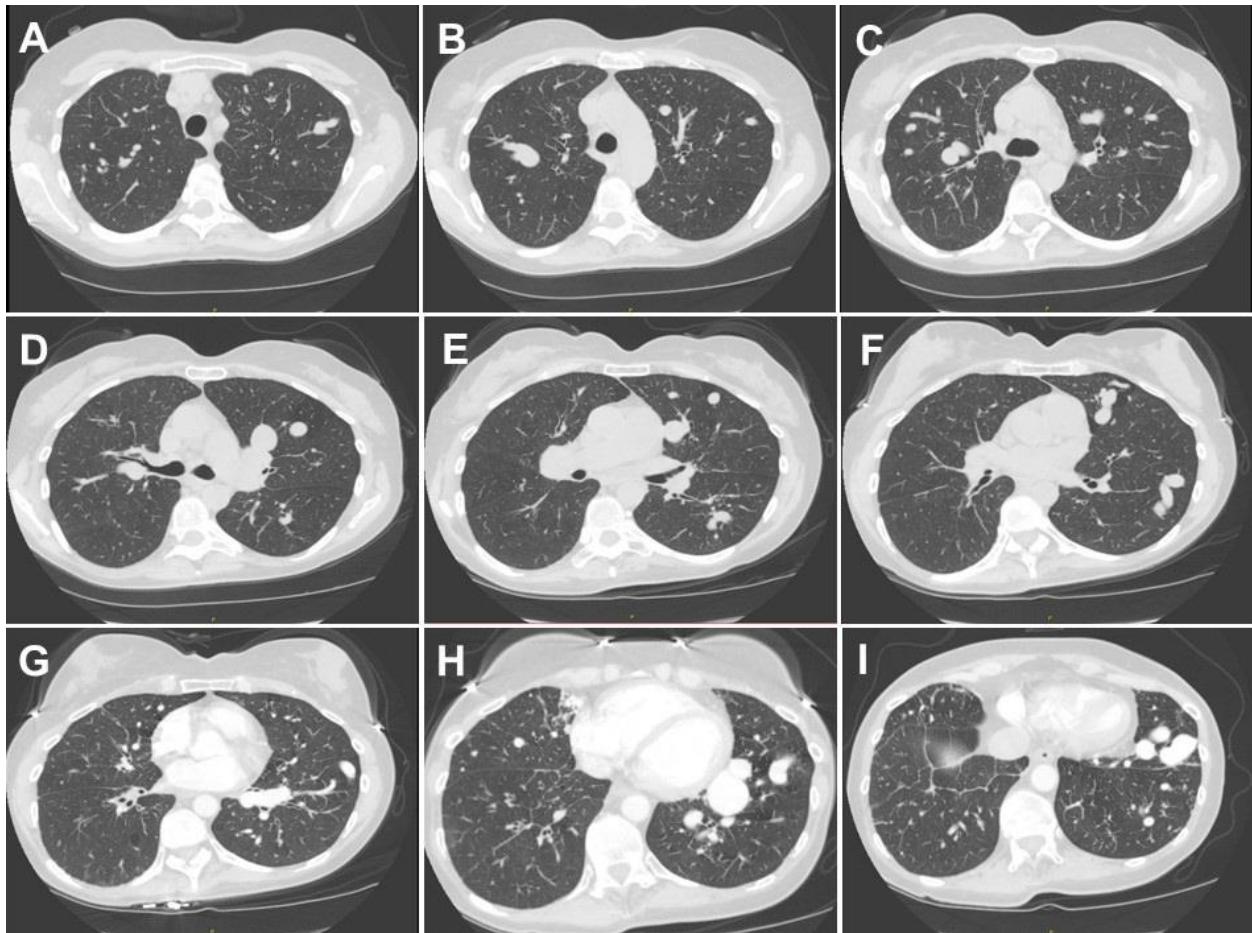


Figure 3. Representative images from thoracic CT scan without contrast (A-F) and with contrast (G-I).

What is the ***most likely diagnosis?***

1. Aneurysmal dilatation of the pulmonary vein
2. Metastatic disease to the lung
3. Multiple pulmonary artery aneurysms
4. Multiple pulmonary emboli
5. Pulmonary varices

Correct!

- 1. Aneurysmal dilatation of the pulmonary vein**
- 5. Pulmonary varices**

These images represent aneurysmal dilatation of the pulmonary vein, otherwise known as pulmonary varices. Pulmonary emboli would present as blockage of the pulmonary arteries. Multiple metastatic lesions would have a more delayed blush rather than rapidly appearing to fill the entire pulmonary vein and would present as discrete nodular opacities, not tortuous, elongated structures.

Which of the following are **causes of pulmonary varices?**

1. Pulmonary hypertension
2. Bechet's disease
3. Mitral valve disease
4. 1 and 3
5. All of the above

Correct!
4. 1 and 3

Bechet's disease, causes pulmonary arterial aneurysms (2). Pulmonary varices are rare with only 71 cases reported prior to 1988 (3,4). The varices can be divided into congenital and acquired type cases. Most congenital cases develop during embryonic development, whereas acquired cases mainly accompany mitral valve disease, coarctation of the aorta, or pulmonary venous stenosis (4). Acquired varices may be classified into three types, namely: saccular type, tortuous type and confluent type. Most of the varices seen in patients with valvular disease have been of the confluent type (62%), however tortuous-type varices have also been seen in some cases (19%) (4). None of the saccular type cases, however, were accompanied by valvular disease. The location in 71 cases were RLL-60%, LUL- 17%, RUL -8%, RML- 4%, and LLL-4%. There were no prior reports of bilateral lower lobe varices.

The patient underwent pulmonary angiography confirmed the presence of the pulmonary varices (Figure 4).

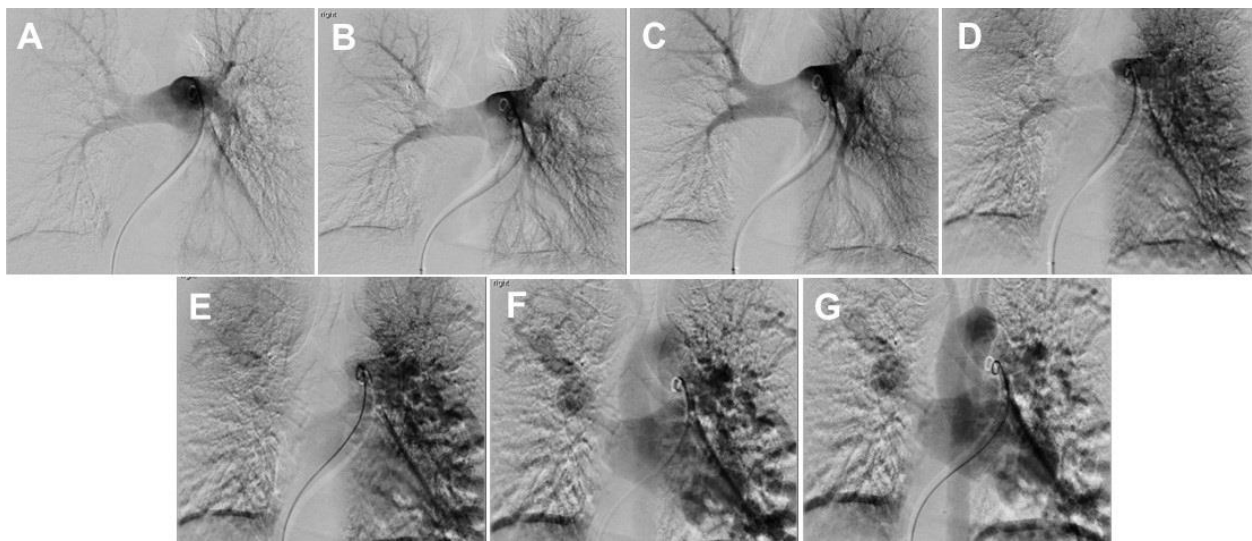


Figure 4. Sequential images from the pulmonary angiogram demonstrating the presence of the varices.

Pulmonary artery pressure was normal.

Which of the following should be done to **treat pulmonary varices?**

1. Embolize the appropriate pulmonary veins
2. Embolize the artery feeding the affected pulmonary veins
3. Prednisone to reduce pulmonary vein wall inflammation
4. Resect the pulmonary veins
5. No treatment is necessary

Correct!

5. No treatment is necessary

No treatment is generally necessary for pulmonary varices (3,4). Very rarely complications such as recurrent infection, rupture with hemorrhage/hemoptysis, or cerebral emboli have resulted which may necessitate intervention.

References

1. Choosing Wisely. Health checkups. 03/14. Available at: <http://www.choosingwisely.org/patient-resources/health-checkups/> (accessed 2/12/19).
2. Neuyen ET, Silva CI, Seely JM, Chong S, Lee KS, Muller NL. Pulmonary artery aneurysms and pseudoaneurysms in adults: Findings at CT and radiography. *AJR Am J Roentgenol.* 2007;188:W126–34. [\[CrossRef\]](#) [\[PubMed\]](#)
3. Tajiri S, Koizumi J, Hara T, *et al.* A case of pulmonary varix associated with superior pulmonary vein occlusion. *Ann Vasc Dis.* 2012;5(3):381-4. [\[CrossRef\]](#) [\[PubMed\]](#)
4. Uyama T, Monden Y, Harada K, *et al.* Pulmonary varices: a case report and review of the literature. *Jpn J Surg.* 1988 May;18(3):359-62. [\[CrossRef\]](#) [\[PubMed\]](#)